Manual Therapy 15 (2010) 305–314

Contents lists available at ScienceDirect

Manual Therapy

journal homepage: www.elsevier.com/math

Masterclass

Thoracic outlet syndrome Part 2: Conservative management of thoracic outlet

L.A. Watson [a,b], T. Pizzari [b,*], S. Balster [a]

[a] LifeCare Prahran Sports Medicine Centre, 316 Malvern Road, Prahran, VIC 3181, Australia
[b] Musculoskeletal Research Centre, La Trobe University, Bundoora VIC 3086, Australia

ARTICLE INFO

Article history:
Received 10 March 2009
Received in revised form
23 September 2009
Accepted 1 March 2010

Keywords:
Thoracic outlet syndrome
Conservative management
TOS
Physical therapy

ABSTRACT

Thoracic outlet syndrome (TOS) is a symptom complex attributed to compression of the nerves and vessels as they exit the thoracic outlet. Classified into several sub-types, conservative management is generally recommended as the first stage treatment in favor of surgical intervention. In cases where postural deviations contribute substantially to compression of the thoracic outlet, the rehabilitation approach outlined in this masterclass will provide the clinician with appropriate management strategies to help decompress the outlet. The main component of the rehabilitation program is the graded restoration of scapula control, movement, and positioning at rest and through movement. Adjunctive strategies include restoration of humeral head control, isolated strengthening of weak shoulder muscles, taping, and other manual therapy techniques. The rehabilitation outlined in this paper also serves as a model for the management of any shoulder condition where scapula dysfunction is a major contributing factor.

1. Introduction

Thoracic outlet syndrome (TOS) is a symptom complex characterized by pain, paresthesia, weakness and discomfort in the upper limb which is aggravated by elevation of the arms or by exaggerated movements of the head and neck (Lindgren and Oksala, 1995). Part one of this two-part article series outlined the classification, aetiology, varying clinical presentations, subjective and physical assessment, differential diagnoses and management principles of TOS. The purpose of this paper is to comprehensively describe one treatment approach for the conservative management of TOS.

2. Classification, aetiology, & management

As noted in Part one, TOS is often categorized into two specific clinical entities: Vascular TOS and Neurological TOS (Atasoy, 1996; Rayan, 1998; Sharp et al., 2001) and further sub-divided into arterial and venous TOS under the vascular umbrella and true neurological TOS and symptomatic TOS (sTOS) under the neurological heading (Fig. 1).

The majority of patients presenting with TOS will fall under the sTOS classification (Wilbourn, 1990; Rayan, 1998; Davidovic et al., 2003). sTOS may be aggravated by postural or occupational stressors with repetitive overuse and associated soft tissue adaptations causing intermittent compression of the neurovascular complex (Mackinnon and Novak, 2002).

In the absence of any acute or progressive neurological or vascular lesion, conservative treatment is often recommended as the first stage of management for all sub-types of TOS and surgery is only considered if this fails (Sharp et al., 2001; Mackinnon and Novak, 2002). Conservative management may involve medication, injection therapy, rest, modification of aggravating activities, physiotherapy or a combination of all strategies. The majority of the studies published on TOS highlight physiotherapy strengthening exercises and postural re-educational drills as being the mainstay of any conservative management programme for TOS (Aligne and Barral, 1992; Kenny et al., 1993; Jamieson and Chinnick, 1996; Urschel and Razzuk, 1997; Molina, 1998; Athanassiadi et al., 2001; Mackinnon and Novak, 2002; Wright and Jennings, 2005; Cagli et al., 2006). However specifics of the programmes are rarely given and outcome measures and expected time frames for potential recovery are not included.

The conservative physiotherapy regimen outlined in this article will be suitable for patients presenting with TOS where there is a strong postural contribution to their symptoms. In particular, in cases of TOS where the scapula mechanics are poor and the patient presents with the dropped shoulder condition (scapula depressed and/or downwardly rotated, and/or anteriorly tilted) (Ranney, 1996).

3. Dropped shoulder condition

Many forms of scapula asymmetry may well exist in TOS populations, but in the limited research that has been done, scapula or

* Corresponding author. Tel.: +61 3 94795872.
E-mail address: t.pizzari@latrobe.edu.au (T. Pizzari).

1356-689X/$ – see front matter © 2010 Elsevier Ltd. All rights reserved.
doi:10.1016/j.math.2010.03.002

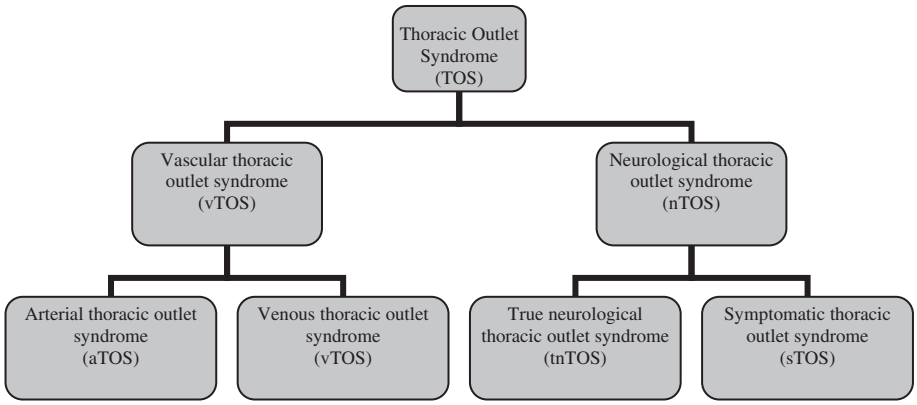

Fig. 1. Sub-types of thoracic outlet syndrome.

shoulder girdle depression or "drooping" has been consistently observed (Kenny et al., 1993; Walsh, 1994; Pascarelli and Hsu, 2001; Skandalakis and Mirilas, 2001).

Scapula depression will lead to an alteration of the anatomical alignment of the structures in both the cervical and thoracic outlet (Telford and Mottershead, 1948; Kai et al., 2001; Skandalakis and Mirilas, 2001) (Fig. 2). It may potentially lead to tractional stress being placed on the nerve, vascular and muscular elements as well as compression as the clavicle descends closer towards either the first rib or any other bony element present. Elevation of the shoulder girdle can alleviate these stressors and potentially lead to "decompressing" the thoracic outlet (Kitamura et al., 1995). The management approach described in this article is designed to elevate the shoulder girdle and restore scapula control.

4. Clinical presentation: scapula position

One of the consistent objective findings that we have observed and measured in cases of sTOS is that the scapula can be depressed at rest (Fig. 3) on the symptomatic side compared to the other side (in unilateral TOS) and to the normative data in cases of bilateral TOS (Kai et al., 2001).

Importantly it is not only at rest that the scapula demonstrates dysfunction but also through elevation motions such as abduction and flexion. In abduction, patients with dropped shoulder TOS (dsTOS) frequently demonstrate late and insufficient upward rotation of the scapula compared to the other side and/or to normal (Figs. 4 and 5). This can often lead to an apparent restriction of abduction range but the deficit is due to inadequate shoulder girdle muscle control and reduced upward rotation of the scapula. Abduction is usually the most provocative motion in dsTOS and it often reproduces the patient's pain, neurological or vascular symptoms, especially if sustained as part of a provocation test (refer to article 1). In flexion, the same tendency for depression and downward rotation is seen but is often over-shadowed by an obvious winging of the scapula due to serratus anterior insufficiency (Mackinnon and Novak, 2002).

Increased anterior tilt of the scapula is also commonly identified in sTOS (Sucher, 1990; Aligne and Barral, 1992; Press and Young, 1994; Walsh, 1994) and it is frequently coupled clinically with increased downward rotation of the scapula.

5. Clinical presentation: scapula muscle control

Although no EMG research exists examining muscle characteristics in a TOS patient population, it is conceivable that alterations in recruitment, intensity and force of shoulder girdle

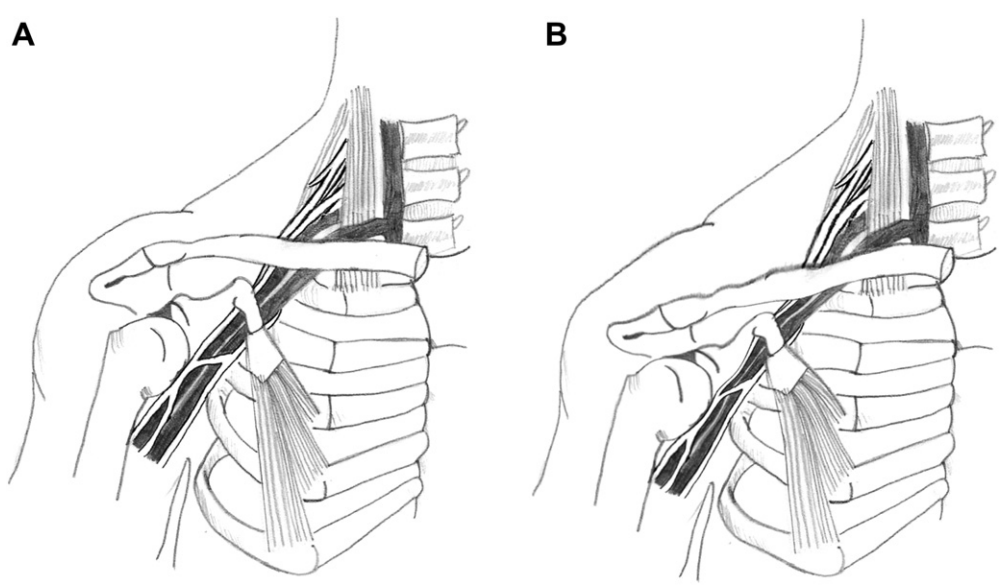

Fig. 2. Thoracic outlet anatomy. A: Normal position of the shoulder girdle. B: Scapula depression causing an alteration of the anatomical alignment of the structures in both the cervical and thoracic outlet.

Fig. 3. Measurement of scapula elevation/depression. The patient is positioned in relaxed standing posture. A tape measure is attached (via piece of tape) to the C7 spinous process. It is then let to drop down the length of the thoracic spine. A second piece of tape may be utilized to attach the tape measure to the spine distally (plumb line). With a second tape measure the therapist may measure across from the inferior angle of the scapula, the end of the spine of the scapula and the acromioclavicular joint to the plumb line. The therapist can then make a note of 1) the centimetre reference point that correlates to the vertical level of each of the three bony landmarks. 2) the distance of each of the bony landmarks to the plumb line. The therapist will be able to judge if the scapula is either elevated or depressed, medially or laterally placed. One side is compared to the other to determine if any asymmetry is present. Anything more than 1 cm of asymmetry is thought to be significant (Kibler, 1991).

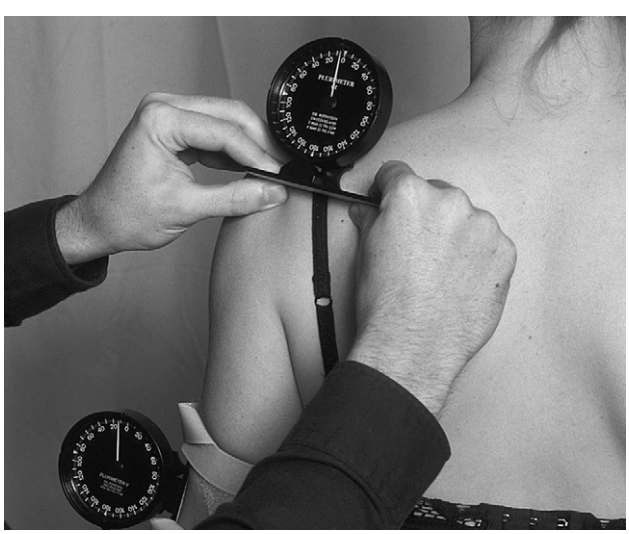

Fig. 4. Measurement of scapula upward and downward rotation at rest. The patient is positioned in relaxed standing posture. One inclinometer is attached to the patient's humerus with two Velcro straps. A second inclinometer is placed on the spine of the patient's scapula – midway between the postero-lateral corner of the acromion and the end of the spine of the scapula. A measurement of the patient's resting humeral abduction angle is taken and a measurement of the scapula's upward/downward rotation at rest.

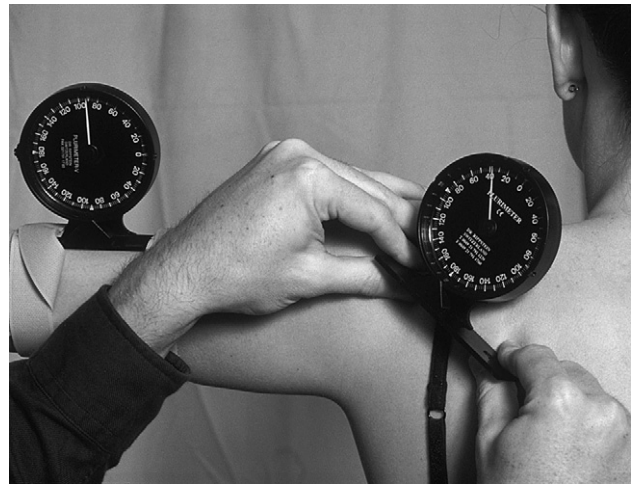

Fig. 5. Measurement of the scapula's position through range of motion. The patient moves their arm into abduction or flexion. The patient may pause at any position through range that the therapist wants to examine (e.g. symptom onset). A measurement of upward/downward rotation of the scapula is taken and the humeral angle. This may be performed all the way through range so that a pattern of scapula motion through range can be determined.

musculature may lead to the aberrant scapula control that has been observed and measured clinically in our patient population with dsTOS.

Clinical manual muscle strength tests performed by these authors with a hand-held strength dynamometer (Power Track II™, USA) have consistently demonstrated decreased strength in many shoulder girdle muscles in patients with dsTOS. There is often a general weakness in shoulder girdle function in the symptomatic compared to the asymptomatic side, in particular in upper and middle trapezius. Substitution or increased consistency of recruitment by other muscle groups such as rhomboids, levator scapulae and pectoralis minor may also occur, leading to the scapula asymmetries commonly observed: downward rotation, depression and anterior tilt of the scapula.

Scapula dysfunction is not only seen in dsTOS with active motions but in response to loading strategies as well. When resisted humeral motion tests (such as resisted external rotation) (Fig. 6) are performed, scapula dyskinesia often becomes more apparent as the scapula is forced to stabilize itself and hold form against the thorax while humeral force is generated.

6. Clinical presentation: scapula correction

The final clinical assessment finding that may indicate that aberrance in scapula mechanics is implicated in either the development or progression of some forms of TOS, is the observation that correction of the scapula asymmetry will frequently alleviate or improve the patients' symptoms (Refer to Part 1). The amount and direction of correction required depends on the position of the scapula but usually the manoeuvre involves elevation and upward rotation of the scapula, trying to maintain the scapula at a similar level to the unaffected side or in the position that achieves the best symptom relief.

Correction manoeuvres can be applied to any assessment position, including loaded tests such as glenohumeral external rotation. If correction of the scapula improves symptoms (pain, weakness, distal symptoms, range of motion) due to better biomechanical performance of the shoulder girdle then logically correction of the scapula position should be addressed in the patient's rehabilitation.

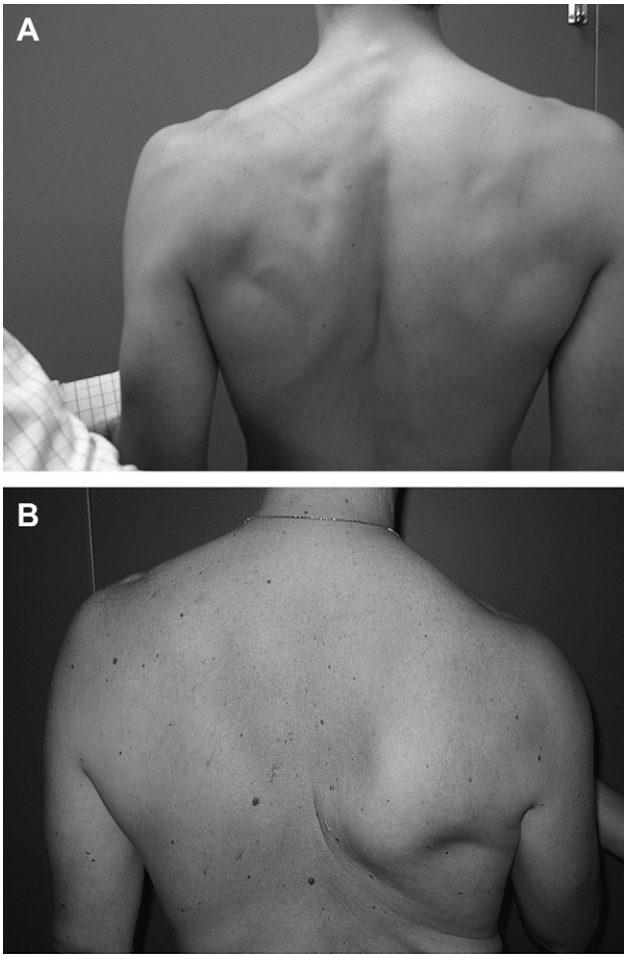

Fig. 6. Dynamic External Rotation Scapula Stability Test. Patient is positioned in relaxed standing posture, examiner behind patient. External rotation of the humerus is resisted with the patient in 0° of abduction. In the normal shoulder the patient usually maintains their resting scapula posture (A). If scapula muscle weakness is present then the scapula will go into a position that reflects the weakness and highlights any dominant strategies (B). For example if upper trapezius is weak and levator scapulae +/− rhomboids are dominant then the scapula will pull into downward rotation. If serratus anterior is weak and pectoralis minor is dominant then the scapula will wing and pull into anterior tilt. Varying combinations of scapula asymmetry may be seen.

7. Rehabilitation overview

The cornerstone of this exercise program is firstly to focus on establishing normal scapula muscle recruitment and control in the resting position. Once this is achieved then the program is progressed to maintaining scapula control while both motion and load are applied. The programme begins in lower ranges of abduction and is gradually progressed further up into abduction and flexion range until muscles are being re-trained in functional movement patterns at higher ranges of elevation (Fig. 7).

7.1. Scapula setting and control

The aim of the scapula "setting" drills is to have the patient actively place their scapula into a "normalized position" and hold this position while humeral motion is superimposed. The scapula motion can be measured clinically using an inclinometer, allowing the therapist to determine if the patient is getting insufficient or excessive scapula motion occurring at any stage through range of motion (Fig. 5). Comparison can be made to the other side or normative "ideals". The same can occur for medial/lateral shift and elevation/depression of the scapula.

Using three reference points (Fig. 3) the scapula position can be mapped. From the normative data we have collated so far for total shoulder abduction, the inferior angle of the scapula typically moves laterally 8 cm and superiorly by 3 cm, the medial end of the spine of the scapula moves inferiorly 3 cm and laterally by 1.5 cm and the acromion moves superiorly 4 cm and medially by 5 cm. The scapula should tilt posteriorly 30° and rotate externally 25° although clinically this is very difficult to measure objectively. In flexion a similar scapula motion pattern is seen (McClure et al., 2001; Bourne et al., 2007). Small deviations in scapula control are expected, it is the larger obvious asymmetries that need to be assessed.

The overall aim of the scapula control work is to achieve a "neutral" scapula position without over elevation or depression and maintaining control against the thorax with sufficient posterior tilt of the scapula to keep the medial border of the scapula stabilized (Fig. 8). This will be achieved by contribution from all of the scapula stabilizers, but in particular serratus anterior, upper, middle and lower trapezius. The aim of the rehabilitation drills is to have all the muscles activating synchronously such that a net smooth upward rotation of the scapula occurs through range of motion. There is no requirement to "stop" some muscles working (such as rhomboids or levator scapulae) but rather the emphasis is on facilitating and encouraging sufficient firing in any muscles that may be weak, inhibited or slow to switch on in the normal movement strategies.

The muscles most commonly requiring facilitation are upper and middle trapezius, serratus anterior or lower trapezius. These are all tonic stabilizers and direct the use of endurance repetitions in the initial phase of rehabilitation (Mackinnon and Novak, 2002). Patients with TOS have been found to develop fatigue earlier in their upper extremities than healthy individuals (Ozcakar et al., 2004).

7.2. Dosage and progression

The therapist assesses how many repetitions of "setting" the scapula the patient can achieve with good form. The aim is to achieve the "neutral" scapula position without substitution from other scapula stabilizers to the extent that aberrant motions such as increased anterior tilt or downward rotation of the scapula are occurring. If repetitions of 20 can be achieved without fatigue (either physically feeling fatigue in muscles or inability of the patient to control/activate scapula muscles correctly) then this is prescribed three times per day. Once this is achieved the drill needs to be progressed, either by increasing the resistance or by progressing the movement patterns or both if the patient can maintain control. If progression is via motion pattern then usually endurance repetitions are still utilized with low resistance. If progression is via adding a weight then this starts off very low (usually 0.5 kg) as the scapula stabilizers are usually still working in primarily a stabilizing role. The weight is incrementally increased by 0.5 kg until an endurance base is achieved (for most muscle groups two sets of 20 with 2 kg is sufficient). Once any form of resistance is applied the regime is dropped to performing twice a day. Movement control and strength work is always commenced initially through abduction as this is the most commonly affected and symptom producing motion for patients with sTOS (Mackinnon and Novak, 2002).

Once recruitment patterns are achieved then isolated strengthening drills may be given for any specific individual muscle groups that test weak. These are only given if the patient can control the scapula and humeral head position during the range of motion utilized in these loaded positions. While emphasis has been placed here on scapula control, humeral head control is equally important at all stages of rehabilitation. It is important that the therapist assesses humeral head position during any loaded

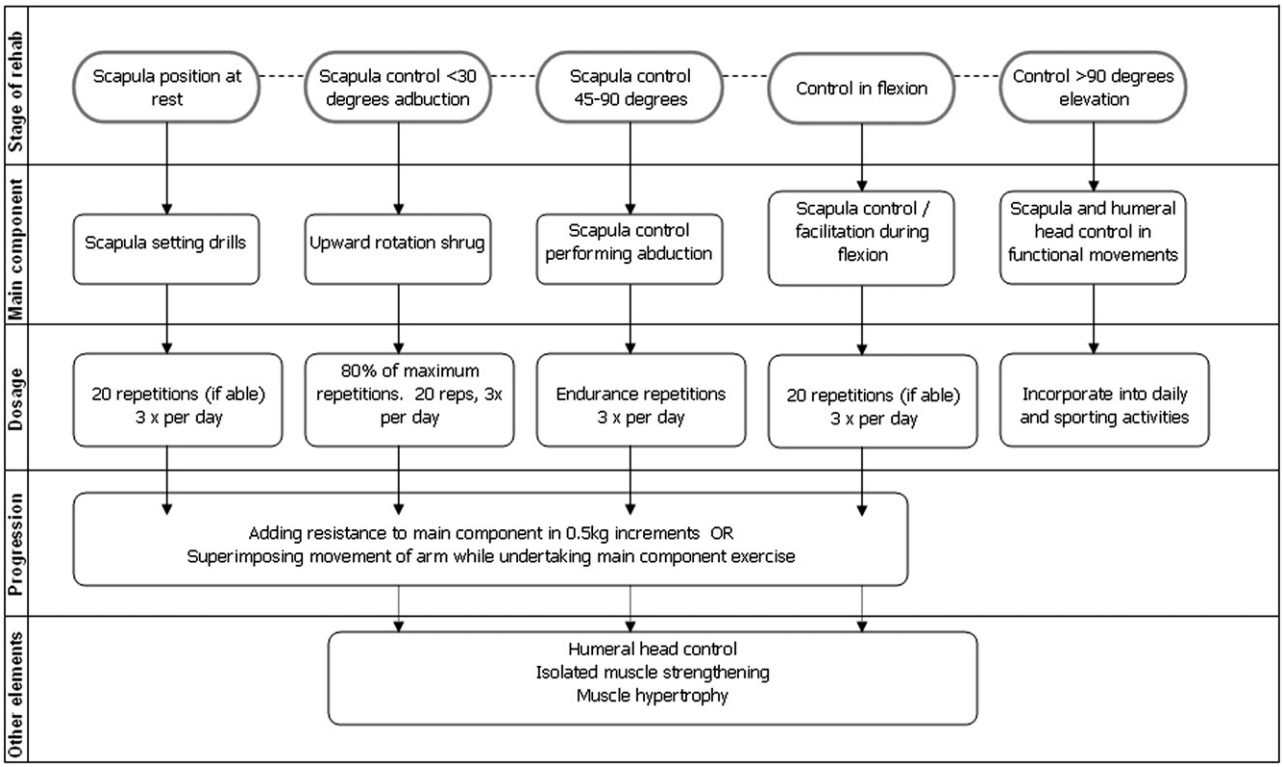

Fig. 7. Rehabilitation overview.

exercise to ensure control is maintained (Fig. 9). Initially light resistance (of either theraband or weights) is utilized with endurance repetitions. For most muscle groups 2 kg max is sufficient for women and 3 kg for men once per day. Hypertrophy drills may eventually be added only if a patients' job or sport requires strength capacity (such as heavy lifting). This is commenced only if a patient is using 3 kg or above in any particular drill and can be progressed as required. Usually the dosage needs to be altered to facilitate

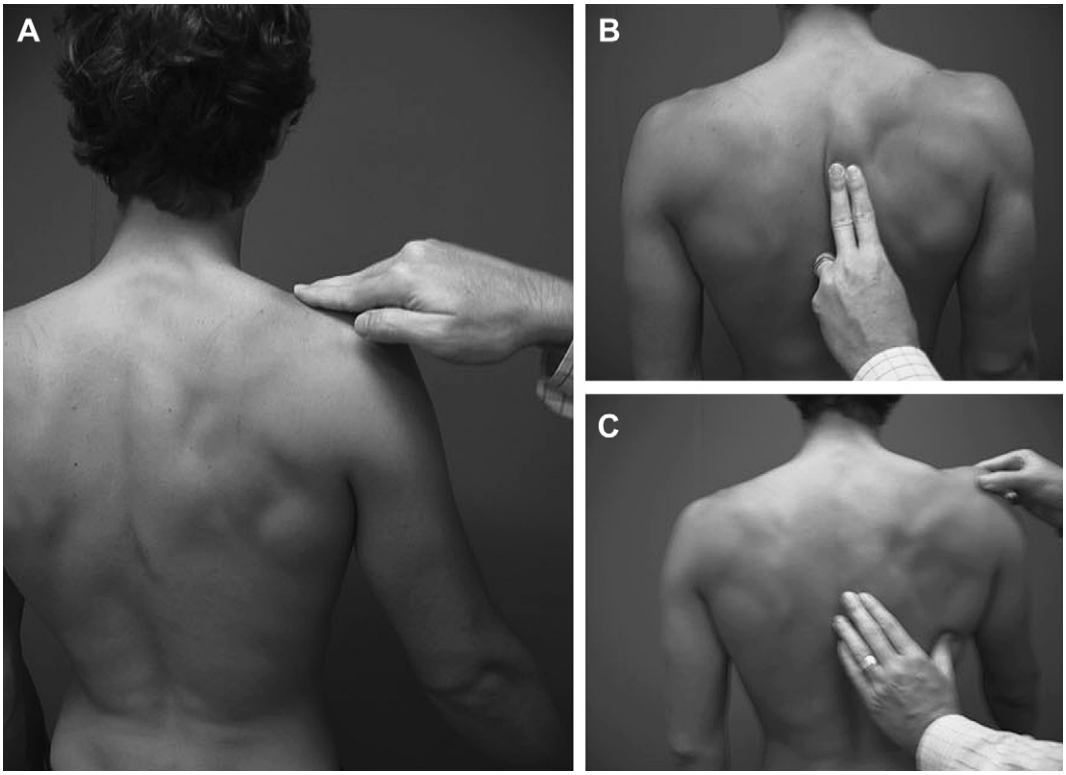

Fig. 8. "Setting" of the scapula involves small isometric contractions. Patient moves or "sets" their scapula into the corrected position using their fingers if possible to feel the contraction. May be a small upward rotation elevation (C) medial glide (B) posterior tilt or scapula depression (A) depending on the asymmetry of the scapula and corrective mechanism required.

Fig. 9. Dynamic Humeral Head Assessment. Patient positioned in relaxed standing. Patient moves arm out into abduction/external rotation combination, usually against resistance (although any motion may be performed). Therapist palpates the humeral head position. Right shoulder – therapist utilizes left hand. Middle finger on the coracoid, index finger on the humeral head and thumb posteriorly on the humeral head. Therapist right hand resists the patient's active motion. Therapist looks for any aberrant humeral head movement or loss of ability to centralize or stabilize the humeral head (usually the humeral head goes anteriorly).

more hypertrophy of the muscle, therefore repetitions of six or eight are selected by four sets (if fatigue allows) only once a day. It may also be beneficial to have "rest" days for muscles to recover and to ensure exercise induced pain is not being created.

Patients are usually discharged on a home program consisting of exercises 3–4 times per week.

8. Rehabilitation program – initial phase

8.1. Aim of this phase

Control of scapula position at rest and in lower ranges of abduction (30° and below).

Commonly in dsTOS the patient will require facilitation of upward rotation of the scapula with a slight amount of elevation. This is achieved by performing an upward rotation shrug in 20–30° of abduction in standing (Fig. 10). Common errors include anterior tilt of scapula or over-retraction by rhomboids. Facilitation techniques include therapist positioning of the scapula with the patient gradually taking over, slight therapist resistance being applied over the acromioclavicular joint, patient self palpation of upper trapezius, visual feedback via mirrors, video monitoring or biofeedback. The patient should perform approximately 80% of their maximum repetition without fatigue or substitution. Once endurance repetitions are achieved then progression can occur by adding a weight into the hand (0.5 kg increments) or resistance of theraband. The amount of resistance is determined by the patients' ability to control the drill without fatigue. If the patient encounters significant cervical pain, an exacerbation of distal symptoms or just finds the exercises too hard then they should be performed in sidelying with the arm supported on a pillow into slight abduction.

Progression can also occur by progressing functional movement patterns. Usually abduction in external rotation is selected first as this is the most functional movement pattern (Fig. 11). If the patient cannot maintain scapula control throughout the whole movement arc, then the movement is broken down so that the patient only performs that part of the arc that they can control or the resistance may need to be reduced. Sometimes the combination motion may be too difficult because there is a co-existing glenohumeral joint weakness (such as external rotation). In this case then the motion is broken down into just that component the patient can control (for example extension against theraband with scapula setting) while specific isolated drills for the weak glenohumeral component are given (such as sidelying external rotation for external rotation deficits). Once sufficient strength is achieved then the combined drill is performed.

As well as ensuring scapula control is maintained during the motion, humeral head position must also be assessed. If there is insufficient control of the humeral head position then specific drills may need to be given to facilitate humeral head control. The most

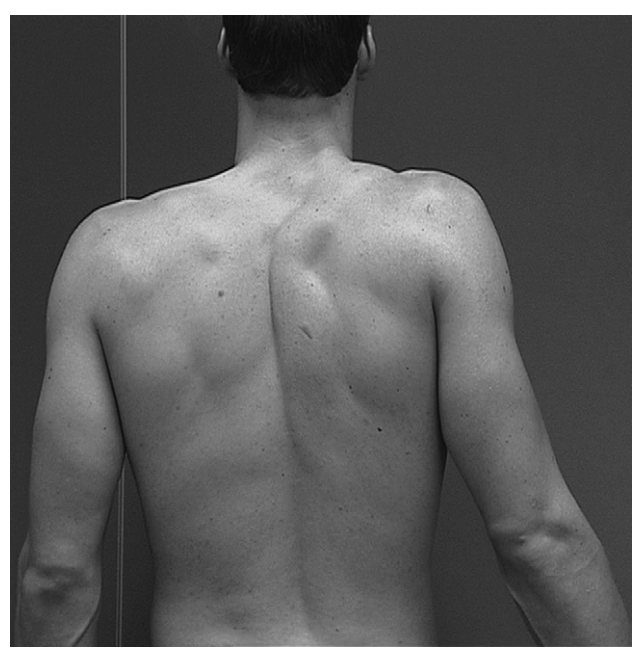

Fig. 10. Upward rotation shrug – performed in 20–30° of abduction in standing. Facilitates upper trapezius. Can be utilized for assessment or rehabilitation.

Fig. 11. Abduction external rotation patterning. Patient "sets" their scapula and then moves their arm into functional motion pattern maintaining both scapula and humeral head control.

common aberrant humeral head position is an increase in anterior placement of the humeral head. A useful strategy to help facilitate co-contraction of the rotator cuff to help stabilize and centralize the humeral head is to facilitate a mid level isometric contraction of the rotator cuff by applying resistance to the humeral head (Dark et al., 2007). The best place to apply resistance is posteriorly over the humeral head via a rubber band (Fig. 12) as this resistance has the added benefit of facilitating the posterior scapula stabilizers. This may be integrated further into movement patterns. Initially emphasis is on slow controlled concentric/eccentric motion drills.

Isolated muscle strengthening drills in these lower ranges of abduction that can be given safely, if required, are; upper trapezius (upward rotation shrugs), external rotation (usually sidelying), posterior deltoid (extension standing), subscapularis (supine internal rotation) and anterior deltoid (supine flexion).

9. Rehabilitation program – exercises in 45–90° of abduction

Aim of this phase:

Control of scapula position above 45° of elevation.
Centralize and control humeral head position.
Load individual muscles that display weaknesses.

Once control is achieved in the lower ranges of abduction, movement control work should be performed in higher ranges of abduction commencing at 45° and progressing towards 70° then 90° of abduction. This can be performed against varying grades of resistance (usually theraband).

Once 90° control is developing, hypertrophy drills for trapezius can be performed in prone horizontal extension if more strength is required. Traditionally these positions have been described for developing middle and lower trapezius strength (Kendall et al., 1971; Ekstrom et al., 2003), but in reality all of the scapula stabilizers will fire in these positions producing a combined effort to stabilize the scapula against the thorax. Precisely which muscle is working is probably not as important as making sure that the scapula is being "set" into a normal stabilizing pattern with upward rotation and stabilization of the medial border of the scapula occurring. Initially the drill is commenced with the elbow bent (short lever) and neutral rotation of the shoulder to avoid any compression to the rotator cuff. If it is required, then long lever strength work can be performed in either internal or external rotation. This would usually only be for those patients who require overhead strength for their occupation or sport (such as painters and swimmers) and only in patients where there is no pathology (such as supraspinatus tendinopathy) that might get aggravated by this position. Prone horizontal extension drills are also very good drills for developing posterior deltoid, supraspinatus, infraspinatus and teres minor. Always ensure that the patient can maintain both scapula and humeral head control throughout the drill.

Isolated muscle strengthening drills in these mid ranges of abduction that can be given safely, if required, are; posterior deltoid (extension in standing against theraband in higher ranges of abduction, elbow bent), subscapularis (supine internal rotation or standing internal rotation in varying degrees of abduction). Middle deltoid performed in sitting to 60° abduction maximum (to avoid any cuff impingement) with elbow flexion can also be performed if required.

10. Rehabilitation program – flexion control

Once reasonable abduction control is established then the therapist needs to re-assess flexion control. Frequently in flexion there is winging of the scapula reflecting weakness and inhibition of serratus anterior. It is tempting to give serratus anterior drills early on in the rehabilitation programme that involve flexion or weight bearing strategies since these have traditionally been prescribed for serratus anterior deficit (Moseley et al., 1992; Ekstrom et al., 2004), however one complication of using these strategies is that pectoralis minor is also recruited early on in the flexion movement. These drills can over-stimulate pectoralis minor recruitment which may potentially propagate the symptoms of sTOS. Abduction external rotation strategies described above are often sufficient to trigger serratus recruitment and control without the risk of over-activating pectoralis minor (Wickham et al., 2009) (Fig. 11). If there is persisting serratus anterior deficit in the flexion movement, especially in the eccentric lowering phase of the motion, the same principles of scapula facilitation and movement control can be applied to a graduated programme emphasising the control of the flexion motion against theraband resistance. The therapist may utilize hand placement to facilitate posterior tilt of the scapula (Fig. 13).

Once flexion control is achieved isolated muscle drills that can be added, as required, are; anterior deltoid (sitting flexion) and serratus anterior (military raise in above 120° of flexion or plane of the scapula elevation).

11. Rehabilitation program – exercises in 90° of abduction and above/functional progressions

The same strategies are employed as for the lower ranges but this is only performed in patients who functionally require these higher ranges of strength, usually an athlete or overhead manual worker. The same principles of rehabilitation can also be incorporated into functional movement patterns such as reproducing a swimming stroke, or emulating the repeated arm movement of typing while maintaining scapula and humeral head control against

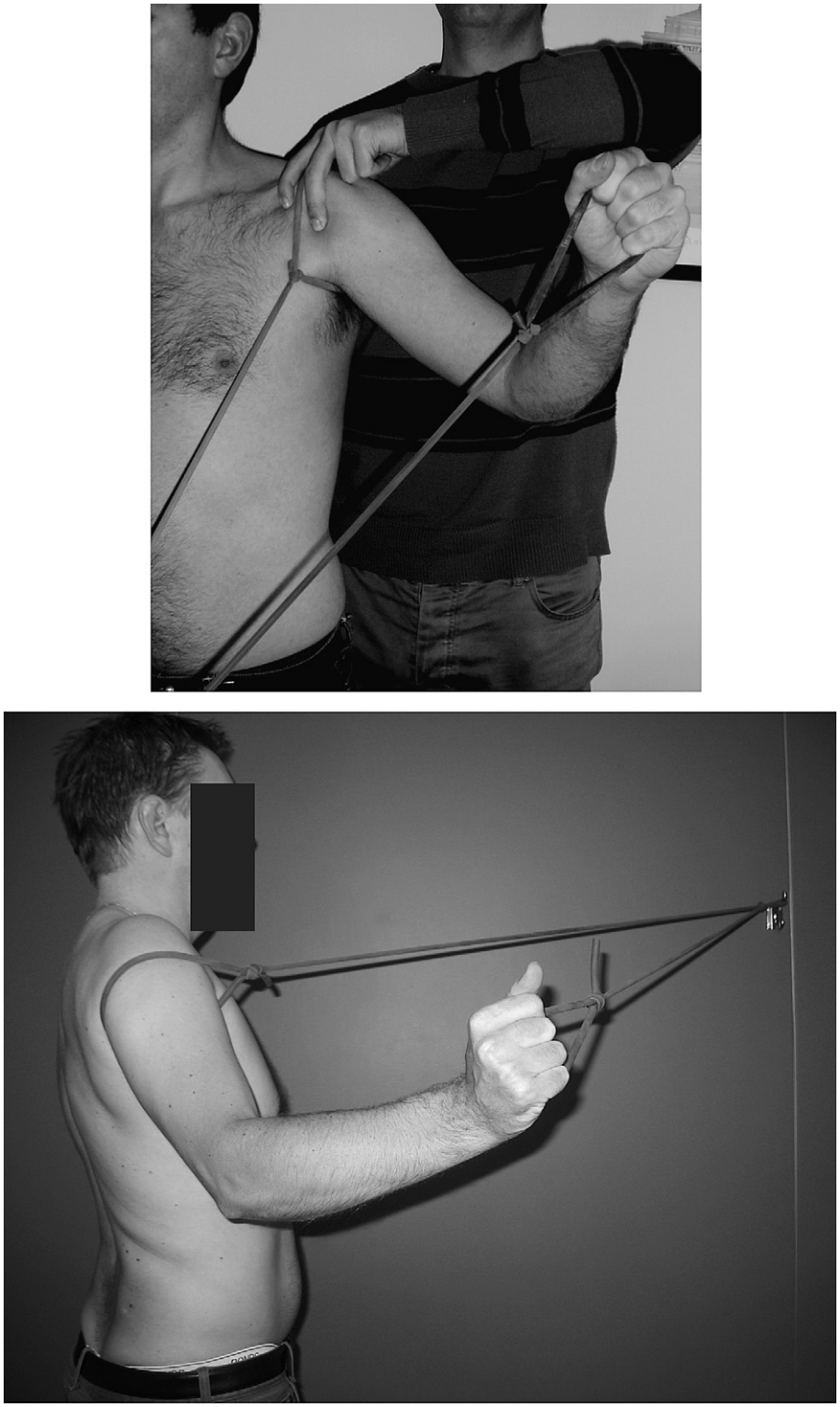

Fig. 12. Facilitation of humeral head control. Therapist utilizes their fingers to apply pressure to the posterior humeral head (or further distally down the arm) and asks the patient to push back against their fingers. Only moderate resistance is applied. This will facilitate co-contraction of the rotator cuff muscles and help resist any aberrant humeral head motion (such as anterior glide). Patient then attaches one theraband proximally to mimic the therapist pressure and another distally in the hand. Patient "sets" their scapula, pushes back into the top rubber band and then pulls out into the functional motion pattern required maintaining both scapula and humeral head control. Endurance repetitions utilized.

light resistance. However, care must be taken with strength work in the overhead position with many cases of TOS since if performed too early many patients' symptoms may be provoked. Strength work in this position is never performed in any patient with any form of vascular TOS as damage to the vascular structures may occur. Initially focus will be on slow control of concentric and eccentric motion but eventually ballistic/plyometric type contractions are encouraged as functionally required.

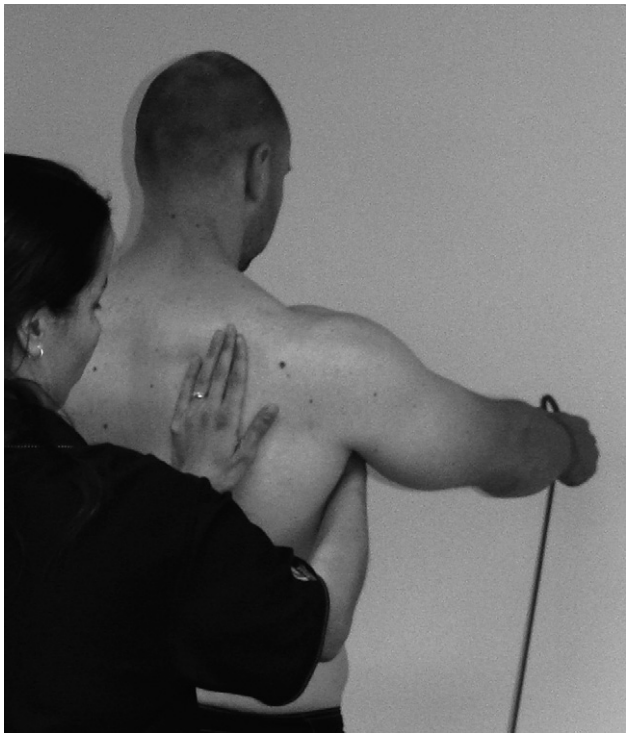

Fig. 13. Therapist facilitates posterior tilt of the scapula (+/− upward rotation) while the patient moves into flexion against theraband resistance.

12. Precautions

In all patients with TOS the therapist must always warn the patient to be on the alert for any alteration or aggravation in either the distal symptoms or swelling, colour changes or temperature. Alteration of the scapula position may potentially relieve symptoms but could, especially in cases of true structural TOS, exacerbate symptoms. In particular, over-retraction of the scapula may create a relative entrapment of the neurovascular structures behind the pectoralis minor (Falconer and Weddell, 1943).

12.1. Care with external rotation

Careful attention to the patients' symptoms needs to occur when adding external rotation to the upward rotation shrug drill or indeed to any of the exercises performed in the program. In some patients it appears that adding on the external rotation manoeuvre alters the relationship, position or tension on the neurovascular structures within the scalene triangle. Adding external rotation may provoke the neurological symptoms by increasing traction on already tensioned structures, particularly if the neural complex is already deviated or stretched around a structural lesion such as a cervical rib. In some patients external rotation cannot be performed until sufficient elevation of the scapula has occurred to "decompress" the outlet. In others, external rotation cannot be performed at all.

13. Taping

If scapula correction assists with symptoms then tape may be utilized to provide support for the shoulder girdle. Taping is for short term use while the patient develops sufficient muscular control to support their shoulder girdle themselves. The taping technique developed by these authors for TOS was first published in Watson and Dalziel (1997). The "axillary sling" technique was designed to create scapula elevation and upward rotation (Fig. 14). It is only recommended for use in those patients whose symptoms are improved with scapula elevation. The armpit should be shaved prior to the application of tape and the usual care when utilizing taping techniques adhered to.

14. Other treatment techniques

While strengthening of the shoulder girdle is the mainstay of the rehabilitation approach, other treatment techniques may be added. TOS is frequently multifactorial in its development and therefore unlikely to be uni-faceted in its solution. Cervical, thoracic and first rib mobilization techniques, massage, scalene and pectoral muscle stretches as well as neuromeningeal treatment techniques may all have a role to play in treating the various subgroups of TOS (Mackinnon and Novak, 2002). In addition, often steps need to be taken to try to modify or improve the workplace ergonomics since one of the key precipitating events in this group of patients is a typical postural deterioration (Pascarelli and Hsu, 2001).

15. Expected outcomes

At present there are no clinical outcome questionnaires that have been validated in a TOS patient population. Currently these authors utilize a combination of L'Insalata et al's. (1997) shoulder rating questionnaire and Kirkely et al. (2003) patient specific questionnaire when assessing outcome in this population. Objective outcome measures of interest include change in shoulder

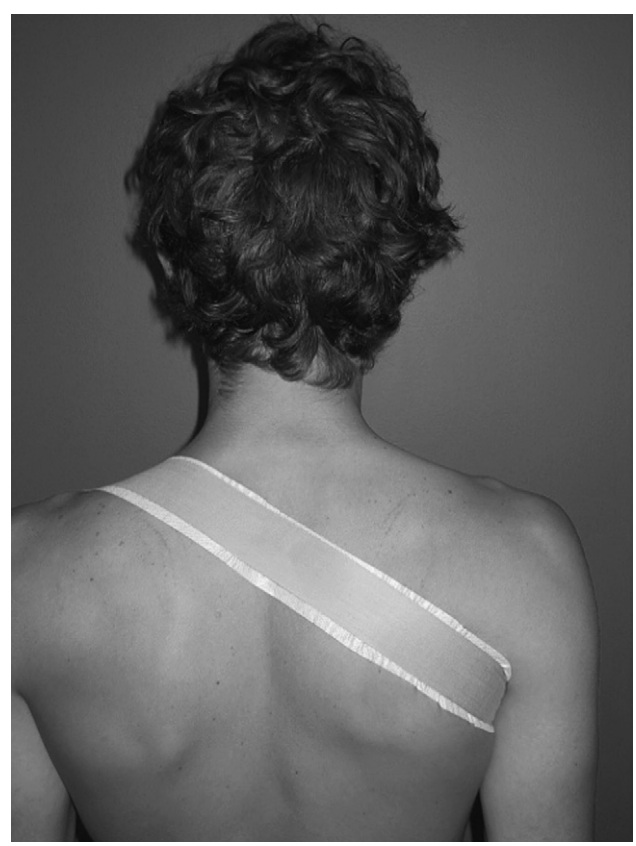

Fig. 14. The "axillary sling" technique was designed to create scapula elevation and upward rotation.

girdle strength, scapula position at rest and in motion and time to onset of symptoms during provocation testing. Clinical data has shown us that patients can reliably achieve a change in their scapula resting position by 6 weeks of rehabilitation and an alteration in both their shoulder girdle strength and scapula motion through range by 12 weeks of rehabilitation. Concurrent with this is usually a gradual improvement in the patients' signs and symptoms and an improvement in their functional state. Some patients have completed their program and have achieved normal strength and scapula measurements by 12 weeks, others take 6 months and some never progress past a plateau or fail to complete the program. It is reasonable that if this program is going to benefit your patient, then there should be some subjective and objective improvement in symptoms by six to eight weeks.

16. Conclusion

The rehabilitation approach outlined in this article is based on our clinical experience of working with patients with TOS and at the current time we can only describe anecdotal evidence of success. There is a need for good quality research in this area to determine the most appropriate treatment path for the different TOS sub-types and the optimal composition of conservative rehabilitation.

References

Aligne C, Barral X. Rehabilitation of patients with thoracic outlet syndrome. Annals of Vascular Surgery 1992;6(4):381–9.

Atasoy E. Thoracic outlet compression syndrome. Orthopedic Clinics of North America 1996;27(2):265–303.

Athanassiadi K, Kalavrouziotis G, Karydakis K, Bellenis I. Treatment of thoracic outlet syndrome: long-term results. World Journal of Surgery 2001;25 (5):553–7.

Bourne DA, Choo AM, Regan WD, MacIntyre DL, Oxland TR. Three-dimensional rotation of the scapula during functional movements: an in vivo study in healthy volunteers. Journal of Bone and Joint Surgery 2007;16(2):150–62.

Cagli K, Ozcakar L, Beyazit M, Sirmali M. Thoracic outlet syndrome in an adolescent with bilateral bifid ribs. Clinical Anatomy 2006;19(6):558–60.

Dark A, Ginn KA, Halaki M. Shoulder muscle recruitment patterns during commonly used rotator cuff exercises: an electromyographic study. Physical Therapy 2007;87(8):1039–46.

Davidovic LB, Kostic DM, Jakovljevic NS, Kuzmanovic IL, Simic TM. Vascular thoracic outlet syndrome. World Journal of Surgery 2003;27(5):545–50.

Ekstrom RA, Bifulco KM, Lopau CJ, Anderson CF, Gough JR. Comparing the function of the upper and lower parts of serratus anterior muscle using surface electromyography. Journal of Orthopaedic & Sports Physical Therapy 2004;34: 235–43.

Ekstrom RA, Donatelli RA, Soderberg GL. Surface electromyographic analysis of exercises for the trapezius and serratus anterior muscles. Journal of Orthopaedic & Sports Physical Therapy 2003;33(5):247–58.

Falconer MA, Weddell G. Costoclavicular compression of the subclavian artery and vein. Lancet 1943;2:539–43.

Jamieson WG, Chinnick B. Thoracic outlet syndrome: fact or fancy? A review of 409 consecutive patients who underwent operation. Canadian Journal of Surgery 1996;39(4):321–6.

Kai Y, Oyama M, Kurose S, Inadome T, Oketani Y, Masuda Y. Neurogenic thoracic outlet syndrome in whiplash injury. Journal of Spinal Disorders 2001;14 (6):487–93.

Kendall HO, Kendall FP, Wadsworth GE. Muscles, testing and function. 2nd ed. Baltimore: Williams and Wilkins; 1971.

Kenny RA, Traynor GB, Withington D, Keegan DJ. Thoracic outlet syndrome: a useful exercise treatment option. American Journal of Surgery 1993;165(2):282–4.

Kibler BW. The role of the scapula in the overhead throwing motion. Contemporary Orthopaedics 1991;22(5):525–32.

Kirkely A, Griffin S, Dainty K. Scoring systems for the functional assessment of the shoulder. Arthroscopy: The Journal of Arthroscopic and Related Surgery 2003;19(10):1109–20.

Kitamura T, Takagi K, Yamaga M, Morisawa K. Brachial plexus stretching injuries: microcirculation of the brachial plexus. Journal of Shoulder and Elbow Surgery 1995;4(2):118–23.

L'Insalata J, Warren R, Cohen S, Altchek D, Peterson M. A self-administered questionnaire for assessment of the symptoms and function of the shoulder. Journal of Bone and Joint Surgery 1997;79-A(5):738–48.

Lindgren KA, Oksala I. Long-term outcome of surgery for thoracic outlet syndrome. American Journal of Surgery 1995;169(3):358–60.

Mackinnon SE, Novak CB. Thoracic outlet syndrome. Current Problems in Surgery 2002;39(11):1070–145.

McClure PW, Michener LA, Sennett BJ, Karduna AR. Direct 3-dimensional measurement of scapular kinematics during dynamic movements in vivo. Journal of Shoulder and Elbow Surgery 2001;10(3):269–77.

Molina JE. Combined posterior and transaxillary approach for neurogenic thoracic outlet syndrome. Journal of the American College of Surgeons 1998;187 (1):39–45.

Moseley Jr JB, Jobe FW, Pink M, Perry J, Tibone J. EMG analysis of the scapular muscles during a shoulder rehabilitation program. American Journal of Sports Medicine 1992;20(2):128–34.

Ozcakar L, Dincer F, Atalay A, Kaymak B, Aksu AE, Akyurek M. Compressive injury of the brachial plexus after axillary arteriography and its further consequences. Joint Bone Spine 2004;71(4):349–51.

Pascarelli EF, Hsu YP. Understanding work-related upper extremity disorders: clinical findings in 485 computer users, musicians, and others. Journal of Occupational Rehabilitation 2001;11(1):1–21.

Press JM, Young JL. Vague upper-extremity symptoms? The Physician and Sportsmedicine 1994;22(7):57–64.

Ranney D. Thoracic outlet: an anatomical redefinition that makes clinical sense. Clinical Anatomy 1996;9(1):50–2.

Rayan GM. Thoracic outlet syndrome. Journal of Shoulder and Elbow Surgery 1998;7(4):440–51.

Sharp WJ, Nowak LR, Zamani T, Kresowik TF, Hoballah JJ, Ballinger BA, et al. Long-term follow-up and patient satisfaction after surgery for thoracic outlet syndrome. Annals of Vascular Surgery 2001;15(1):32–6.

Skandalakis JE, Mirilas P. Benign anatomical mistakes: the thoracic outlet syndrome. American Surgeon 2001;67(10):1007–10.

Sucher BM. Thoracic outlet syndrome–a myofascial variant: part 2. Treatment. Journal of the American Osteopathic Association 1990;90(9):810–2. 817–823.

Telford ED, Mottershead S. Pressure at the cervico-brachial junction; an operative and anatomical study. Journal of Bone and Joint Surgery 1948;30A(2):249–65.

Urschel Jr HC, Razzuk MA. Upper plexus thoracic outlet syndrome: optimal therapy. Annals of Thoracic Surgery 1997;63(4):935–9.

Walsh MT. Therapist management of thoracic outlet syndrome. Journal of Hand Therapy 1994;7(2):131–44.

Watson L, Dalziel R. Conservative treatment of thoracic outlet syndrome by scapula strengthening techniques. In: Skirving AP, editor. Shoulder surgery: the Asian perspective; 1997. p. 219–21. Perth.

Wickham J, Pizzari T, Stansfeld K, Burnside A, Watson L. Quantifying 'norma' shoulder muscle activity during abduction. Journal of Electromyography and Kinesiology 2009;20(2):212–22.

Wilbourn AJ. The thoracic outlet syndrome is overdiagnosed. Archives of Neurology 1990;47(3):328–30.

Wright D, Jennings PR. Thoracic outlet syndrome. Journal of the American Academy of Physician Assistants 2005;18(5):57–8.